

BATINGA AMC Test Report of Hematology Analysis

Hospital Address:SM CITY CDO UPTOWN

Contact number:09061211260

Report No.:2605240007

Medical No.:

Test Time:2026.05.24 14:45:42

Pet Name:COCO

Pet type:Feline

Gender:Female

Age: Year

Sample Type:Whole blood

Owner:

Parameters	Result	Reference range	Low	Normal	High
01. WBC (White blood cell count)	22.97 10 ³ /uL↑	2.87-17.02			
NEU# (Neutrophil count)	20.39 10 ³ /uL↑	2.30-10.29			
NST# (Band neutrophil count)	0.13 10 ³ /uL	0.00-0.80			
NSG# (Segmented neutrophil count)	19.63 10 ³ /uL↑	2.30-12.50			
NSH# (Hypersegmented neutrophil count)	0.63 10 ³ /uL↑	0.00-0.30			
LYM# (Lymphocyte count)	1.40 10 ³ /uL	0.92-6.88			
SLYM# (Small lymphocyte count)	1.40 10 ³ /uL	0.92-6.88			
LLYM# (Large lymphocyte count)	0.00 10 ³ /uL	0.00-0.00			
MON# (Monocyte count)	0.37 10 ³ /uL	0.05-0.67			
EOS# (Eosinophil count)	0.80 10 ³ /uL	0.17-1.57			
BAS# (Basophil count)	0.00 10 ³ /uL	0.00-0.26			
NEU% (Neutrophil ratio)	88.78 %↑	38.00-80.00			
NST/WBC% (Band neutrophil ratio)	0.56 %	0.00-10.00			
NST/NEU% (Band neutrophil ratio)	0.63 %	0.00-15.00			
NSG% (Segmented neutrophil ratio)	85.47 %↑	35.00-75.00			
NSH/WBC% (Hypersegmented neutrophil ratio)	2.75 %	0.00-3.00			
NSH/NEU% (Hypersegmented neutrophil ratio)	3.09 %	0.00-4.00			
LYM% (Lymphocyte ratio)	6.10 %↓	16.00-47.50			
MON% (Monocyte ratio)	1.63 %	1.00-7.60			
EOS% (Eosinophil ratio)	3.49 %	1.00-11.10			
BAS% (Basophil ratio)	0.00 %	0.00-0.70			
02. RBC (Red blood cell count)	9.30 10 ⁶ /uL	6.54-12.20			
HGB (Hemoglobin concentration)	13.00 g/dL	9.80-16.20			
HCT (Hematocrit)	36.18 %	30.30-52.30			
MCV (Mean red cell volume)	38.90 fL	35.90-53.10			
MCH (Mean Hb per RBC)	13.98 pg	11.80-17.30			
MCHC (Mean Hb conc in RBC)	35.94 g/dL↑	28.10-35.80			
RDW-CV (RBC dist width-CV)	22.43 %	20.90-33.60			
RDW-SD (RBC dist width-SD)	17.88 fL	16.00-27.40			
HDW-CV (Hb dist width-CV)	17.20 %	7.00-30.00			
HDW-SD (Hb dist width-SD)	0.24 g/dL	0.20-0.80			
RET# (Reticulocyte count)	4.06 10 ³ /uL	3.00-50.00			
RET% (Reticulocyte ratio)	0.04 %	0.00-1.00			
ETG# (Shadow red cell count)	0.00 10 ¹² /L	0.00-0.06			
ETG% (Shadow red cell ratio)	0.00 %	0.00-2.50			
SPH# (Spherocyte count)	0.95 10 ⁹ /L	0.00-193.66			
SPH% (Spherocyte ratio)	0.01 %	0.00-2.71			
ACA# (Acanthocyte count)	0.00 10 ³ /uL	0.00-0.00			
NRBC# (Nucleated red cell count)	0.00 10 ³ /uL	0.00-0.00			
NRBC/WBC% (Nucleated red cell ratio)	0.00 %	0.00-0.00			
AGG# (Agglutinated red cell count)	0.00 10 ³ /uL	0.00-0.15			
03. PLT (Platelet count)	295.97 10 ³ /uL	151.00-600.00			
MPV (Mean platelet volume)	13.26 fL	11.40-21.60			
PDW (Platelet distribution width)	18.00 fL	9.10-19.40			
PCT (Plateletcrit)	0.39 %	0.17-0.86			
APLT# (Aggregated platelet count)	0.56 10 ³ /uL↑	0.00-0.15			
P-LCC (Large platelet count)	19.77 10 ³ /uL	0.00-103.00			
P-LCR (Large platelet ratio)	6.68 %	0.00-30.00			

BATINGA AMC Test Report of Hematology Analysis

Hospital Address: SM CITY CDO UPTOWN

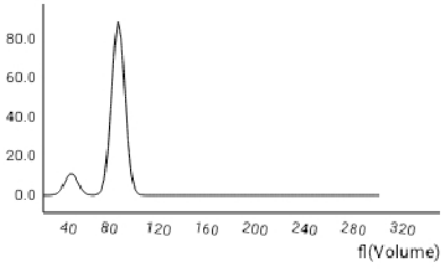
Contact number: 09061211260

Report No.: 2605240007

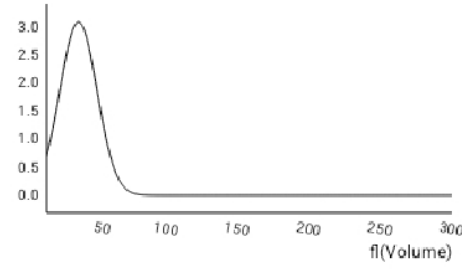
Pet Name: COCO

Pet type: Feline

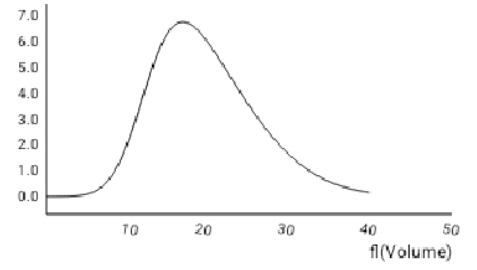
WBC



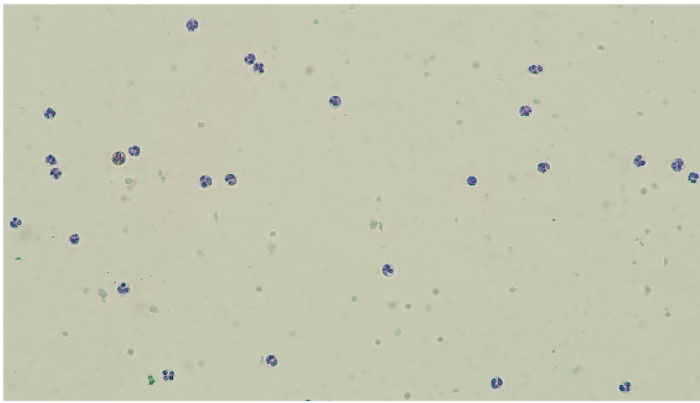
RBC



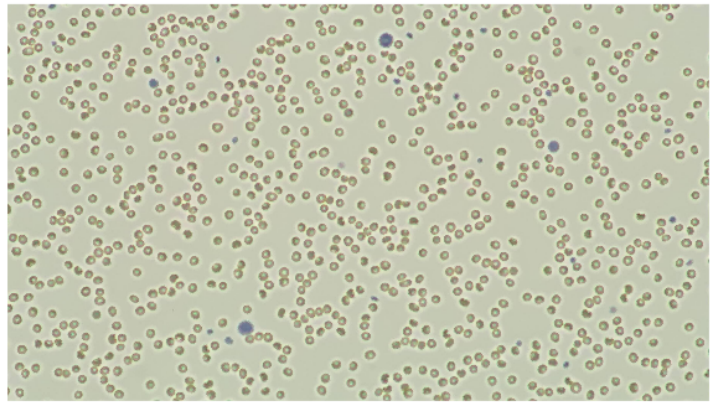
PLT



WBC images



RBC&PLT images

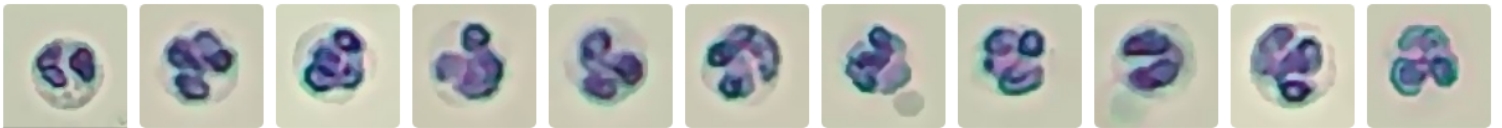

NST# 0.13 $10^3/uL$



STD image Number: 14 sheets/143 images/754 images

NSG# 19.63 $10^3/uL$



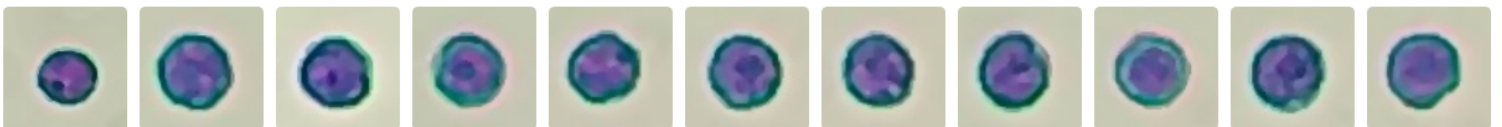STD image Number: 2100 sheets/143 images/754 images

NSH# 0.63 $10^3/uL$



STD image Number: 69 sheets/143 images/754 images

SLYM# 1.40 $10^3/uL$



STD image Number: 147 sheets/143 images/754 images

BATINGA AMC Test Report of Hematology Analysis

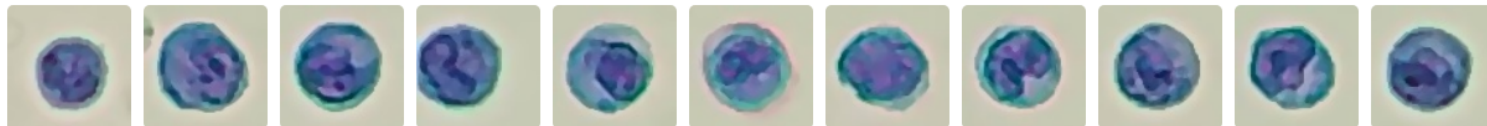
Hospital Address:SM CITY CDO UPTOWN Contact number:09061211260

Report No.:2605240007

Pet Name:COCO

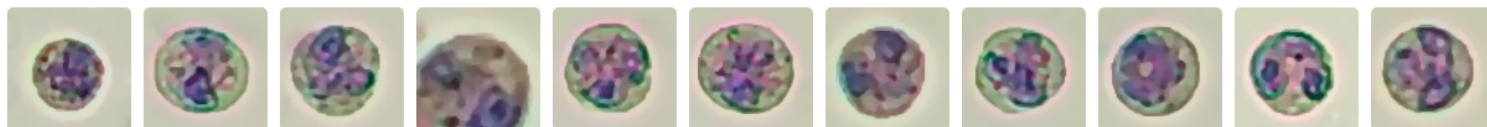Pet type:Feline

MON# 0.37 $10^3/uL$



STD image Number: 39 sheets/143 images/754 images

EOS# 0.80 $10^3/uL$



STD image Number: 88 sheets/143 images/754 images

RET# 4.06 $10^3/uL$




STD image Number: 41 sheets/143 images/754 images

ETG# 0.00 $10^{12}/L$




STD image Number: 1 sheets/36 images/754 images

SPH# 0.95 $10^9/L$



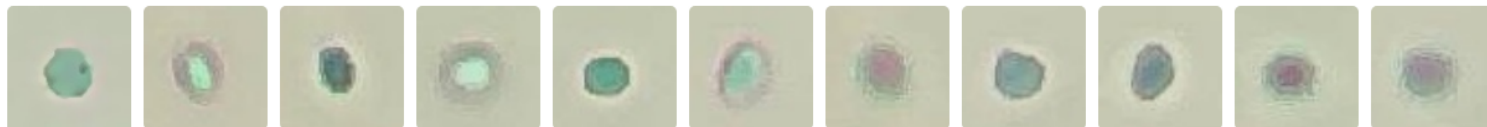STD image Number: 3 sheets/36 images/754 images

APLT# 0.56 $10^3/uL$



STD image Number: 2 sheets/575 images/754 images

P-LCC 19.77 $10^3/uL$



STD image Number: 1138 sheets/575 images/754 images

BATINGA AMC Test Report of Hematology Analysis

Hospital Address:SM CITY CDO UPTOWN

Contact number:09061211260

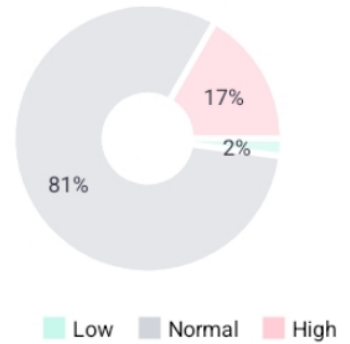
Report No.:2605240007

Pet Name:COCO

Pet type:Feline

Acute Inflammatory Response

Basis for judgment:Significant elevation of neutrophils and segmented neutrophils suggests acute inflammation or bacterial infection, commonly seen in sepsis or localized suppurative infections.



WBC 22.97 $10^3/uL$ \uparrow (2.87-17.02)

-Clinical indication:Presence of acute inflammation or infection (bacterial infection is most typical), tissue injury/necrosis, drug/hormone effects, stress response, or myeloproliferative disorders.

-Basis for judgment:Bacterial infection stimulates the bone marrow to accelerate the release of White Blood Cells (WBC) to fight pathogens; inflammatory responses triggered by trauma, surgery, burns, pancreatitis, etc. ; use of glucocorticoids, colony-stimulating factors, and other drugs can induce elevated WBC; physiological or pathological stress leads to redistribution of WBC, resulting in transient elevation; abnormal proliferation of hematopoietic stem cells leads to persistent and significant elevation of WBC (mostly malignant lesions).

NEU# 20.39 $10^3/uL$ \uparrow (2.30-10.29)

-Clinical indication:Suggests acute inflammation or infection (local or systemic bacterial infection), tissue necrosis, tumors, stress/cortisol effects, hemorrhage, or Hemolysis, granulocytic leukemia, etc.

-Basis for judgment:Neutrophilia is a typical manifestation of acute inflammation (surgery, trauma, infarction, tumor necrosis, thermal injury) or bacterial infection (such as pneumonia, pyelonephritis, cellulitis, pyometra); tumors can secrete granulocyte colony-stimulating factors, etc. , stimulating excessive bone marrow production; Chronic Myeloid Leukemia, Myelodysplastic Syndrome (MDS), etc. , where the bone marrow itself undergoes uncontrolled proliferation; exogenous corticosteroids are the most common drugs leading to iatrogenic neutrophilia.

NSG# 19.63 $10^3/uL$ \uparrow (2.30-12.50)

-Clinical indication:Commonly seen in acute bacterial infection, acute inflammation/tissue injury, stress response, or myeloproliferative lesions, drugs/hormones, poisoning, etc.

-Basis for judgment:Essentially, the bone marrow accelerates the release of mature neutrophils or the retention time of peripheral blood neutrophils is prolonged. Infectious factors (bronchitis, periodontitis, bacterial pneumonia, pyometra, bacterial enteritis, severe sepsis, bacterial peritonitis); non-infectious inflammation/tissue injury (trauma, surgery, burns, acute pancreatitis); transport fright, pain stimulation, surgical stress, history of glucocorticoid medication; Chronic Myeloid Leukemia, Polycythemia Vera, myelofibrosis (malignant, rare but high-risk).

NSH# 0.63 $10^3/uL$ \uparrow (0.00-0.30)

-Clinical indication:Right shift of neutrophil nucleus, commonly seen in Vitamin B 12 or folic acid deficiency, use of antimetabolites, long-term antibiotic or hormone use, metabolic issues, chronic inflammation, etc. Right shift is a sign of declining bone marrow hematopoietic function, often caused by severe systemic exhaustion in serious cases.

-Basis for judgment:Vitamin B 12 or folic acid deficiency affects all rapidly dividing cells, leading to DNA synthesis disorders \rightarrow delayed nuclear development resulting in a right shift. During the recovery phase of inflammation, a transient right shift of neutrophils often occurs. Severe right shift suggests bone marrow function decline; in critical illness, exhaustion of bone marrow hematopoietic function and decreased resistance indicate a poor prognosis.

Possible diseases and basis for inference

Bacterial Infection High

Multiple elevated neutrophil indicators directly point to an acute inflammatory response caused by bacterial infection.

Stress-induced Leukocytosis Medium

Severe stress can lead to increased neutrophil release, manifesting as hematological changes similar to infection.

Chronic Inflammatory Process Low

Persistent elevation of segmented neutrophils may suggest chronic inflammation, but other supporting evidence is lacking.

[1]Boden,E. Andrews,A. (2015). The Black Veterinary Dictionary (22nd Edition). London: Bloomsbury Press.

[2]Latimer,K.S. (2011). Duncan & Plath Veterinary Laboratory Medicine: Clinical Pathology (5th Edition). Ames, Iowa: Wiley Blackwell Publishing House.

[3]Merck Veterinary Manual (2025). Clinical Hematology - Clinical Pathology and Operating Procedures.[4]Weiss,D.J. and Wardrop,K.J. (2010). Schalm Veterinary Hematology (6th Edition). Ames, Iowa: Wiley Blackwell Publishing House.