



Hematology Analysis Report

Patient: JOLINA Species: Canine Patient ID: 121179
 Client: STEPHANIE BORRES Gender: Female Sample No.: 1
 Doctor: Age: 8Years Time of analysis: 2026/05/12 08:46

Para.	Current result	Ref. Ranges
WBC H	80.54 10 ³ /uL	5.32-16.92
Neu# H	73.61 10 ³ /uL	3.05-12.10
Lym#	1.05 10 ³ /uL	0.70-4.95
Mon# H	5.64 10 ³ /uL	0.20-1.38
Eos#	0.16 10 ³ /uL	0.04-1.28
Bas#	0.08 10 ³ /uL	0.00-0.13
Neu% H	91.4 %	42.0-84.0
Lym% L	1.3 %	6.0-40.0
Mon%	7.0 %	2.5-12.0
Eos% L	0.2 %	0.3-11.0
Bas%	0.1 %	0.0-1.0
RBC	6.11 10 ⁶ /uL	5.20-8.69
HGB	12.8 g/dL	11.5-20.1
HCT	37.4 %	35.0-60.0
MCV	61.2 fL	60.0-77.5
MCH	21.0 pg	20.0-27.0
MCHC	34.2 g/dL	30.0-38.0
RDW-CV	14.0 %	11.3-18.9
RDW-SD	32.5 fL	29.1-55.1
PLT	232 10 ³ /uL	140-520
MPV	12.3 fL	7.6-16.1
PDW	16.2	13.8-17.9
PCT	0.286 %	0.120-0.700
P-LCC	95 10 ³ /uL	25-180
P-LCR	41.0 %	10.0-57.0
IPF	2.6 %	0.4-17.1
RET#	94.70 10 ³ /uL	9.00-115.00
RET%	1.55 %	0.16-1.95
IRF	5.3 %	0.0-45.1
LFR	94.7 %	56.0-100.0
MFR	4.6 %	0.0-26.0
HFR	0.7 %	0.0-22.0
RHE	21.2 pg	20.0-28.3

The results only applies to this test sample. Test Instrument: Mindray BC-60R Vet Time of Printing: 2026-05-12 09:00:18



BATINGA ANIMAL MEDICAL CENTER
 TIANO BRO., CAGAYAN DE ORO CITY
 088 857 4112 , 09753453669

Global Pioneer of Comprehensive Animal Medical Solutions
 Better healthcare for all - Since 1991

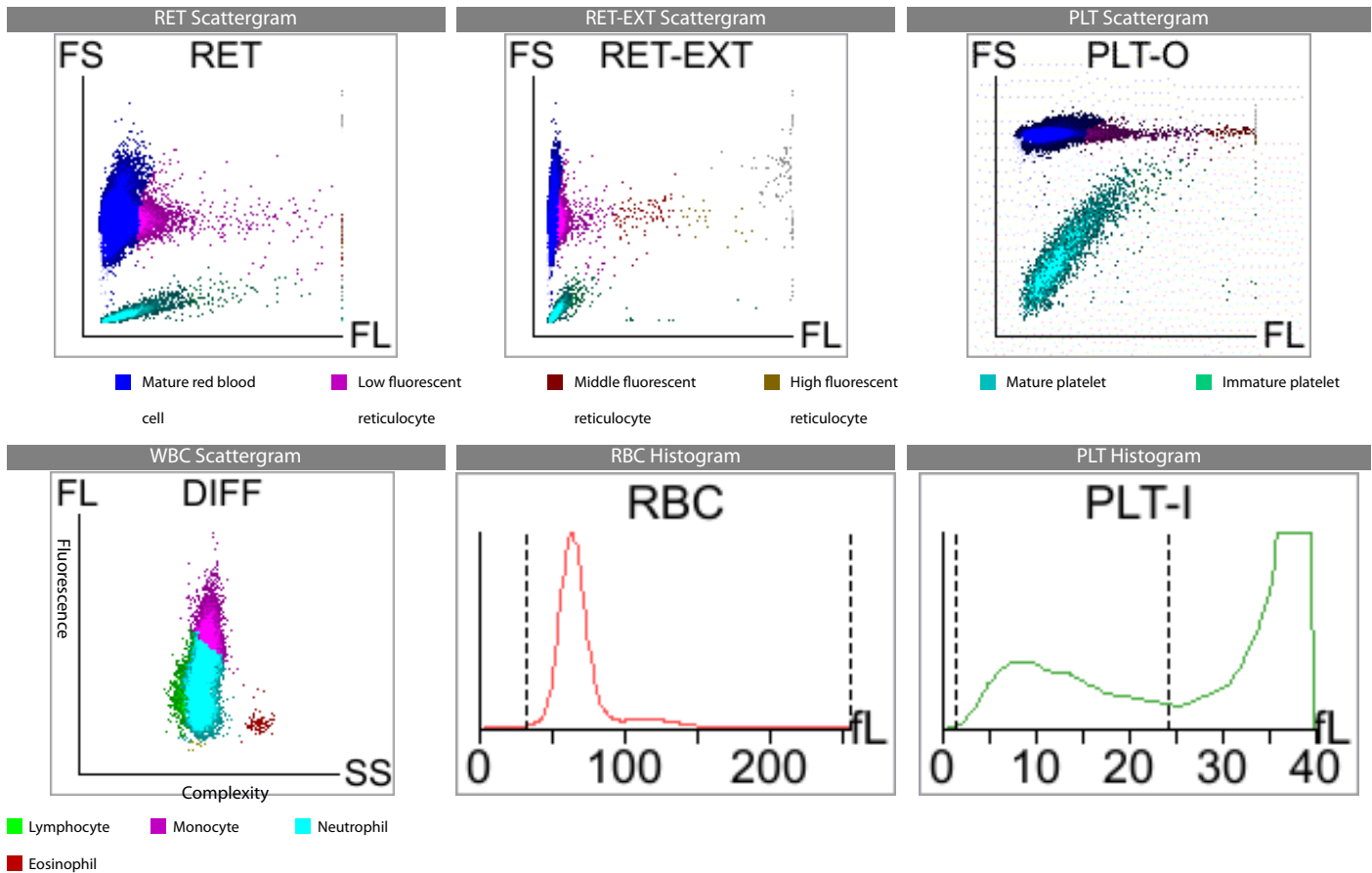
mindray
 animal medical

Hematology Analysis Report



Patient: JOLINA Species: Canine Patient ID: 121179
 Client: STEPHANIE BORRES Gender: Female Sample No.: 1
 Doctor: Age: 8Years Time of analysis: 2026/05/12 08:46

Operator:



Diagnosis implications:

Leucocytosis
WBC Scattergram Abn
PLT Clump

Neutrophilia
Immature Gran

Monocytosis
Band cell suspected

Report Explan.

Leucocytosis	It occurs in bacterial infection, burn, post-operation, malignant tumor, leukemia, etc
Neutrophilia	It occurs in stress response or corticosteroid response, inflammation, granulocytic leukemia, and immune-mediated diseases
Monocytosis	It occurs in stress response or corticosteroid response, bacterial/fungal/protozoal infections, immune-mediated diseases, paraneoplastic reactions (such as lymphoma), monocytic leukemia, etc
WBC Scattergram Abn	The DIFF scattergram may be abnormal due to abnormal lymphocytes, immature granulocytes, blasts, etc
Immature Gran	Possible presence of Immature granulocytes, and it occurs in inflammation, leukemia, and severe bone marrow damage

The results only applies to this test sample.

Test Instrument: Mindray BC-60R Vet

Time of Printing: 2026-05-12 09:00:18



BATINGA ANIMAL MEDICAL CENTER
 TIANO BRO., CAGAYAN DE ORO CITY
 088 857 4112 , 09753453669

Global Pioneer of Comprehensive Animal Medical Solutions
 Better healthcare for all - Since 1991

mindray
 animal medical

Hematology Analysis Report



Patient:	JOLINA	Species:	Canine	Patient ID:	121179
Client:	STEPHANIE BORRES	Gender:	Female	Sample No.:	1
Doctor:		Age:	8Years	Time of analysis:	2026/05/12 08:46

Report Explan.

Band cell suspected	Possible presence of band cells and/or toxic neutrophils, and it occurs in infection and inflammation
PLT Clump	Possible presence of PLT clump, and it occurs in difficult blood collection, anticoagulant-dependent thrombocytopenia

Note: Due to the complexity and individuality of disease diagnosis, the report interpretation is only for your reference. Please consult your doctors for clinical diagnosis results. The results only applies to this test sample.

Test Instrument: Mindray BC-60R Vet Time of Printing: 2026-05-12 09:00:18



BATINGA ANIMAL MEDICAL CENTER
TIANO BRO., CAGAYAN DE ORO CITY
088 857 4112 , 09753453669

Global Pioneer of Comprehensive Animal Medical Solutions
Better healthcare for all - Since 1991

mindray
animal medical